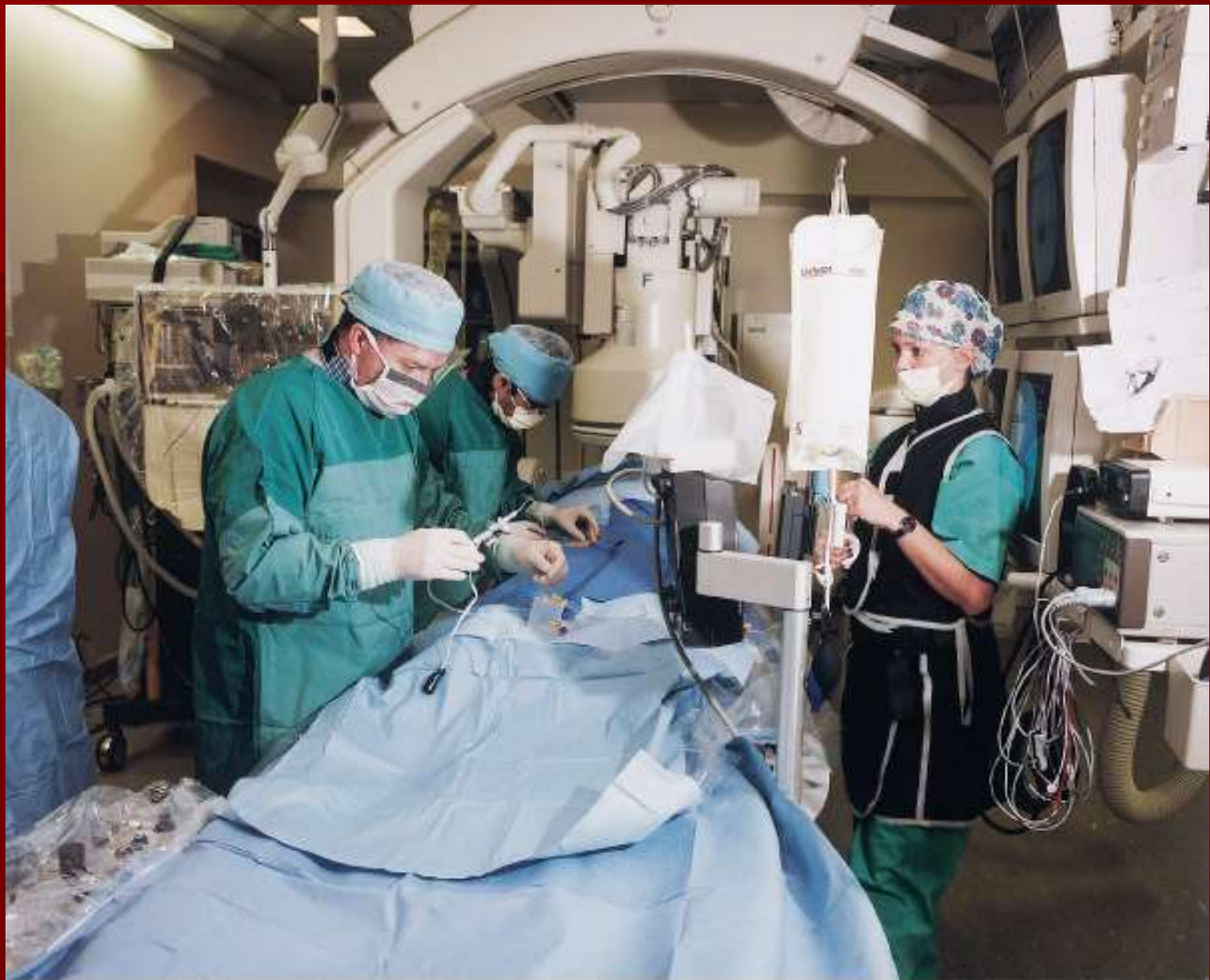

Angiography

Is the general term that describes the radiologic examination of vascular structures within the body after the introduction of an iodinated contrast medium or gas



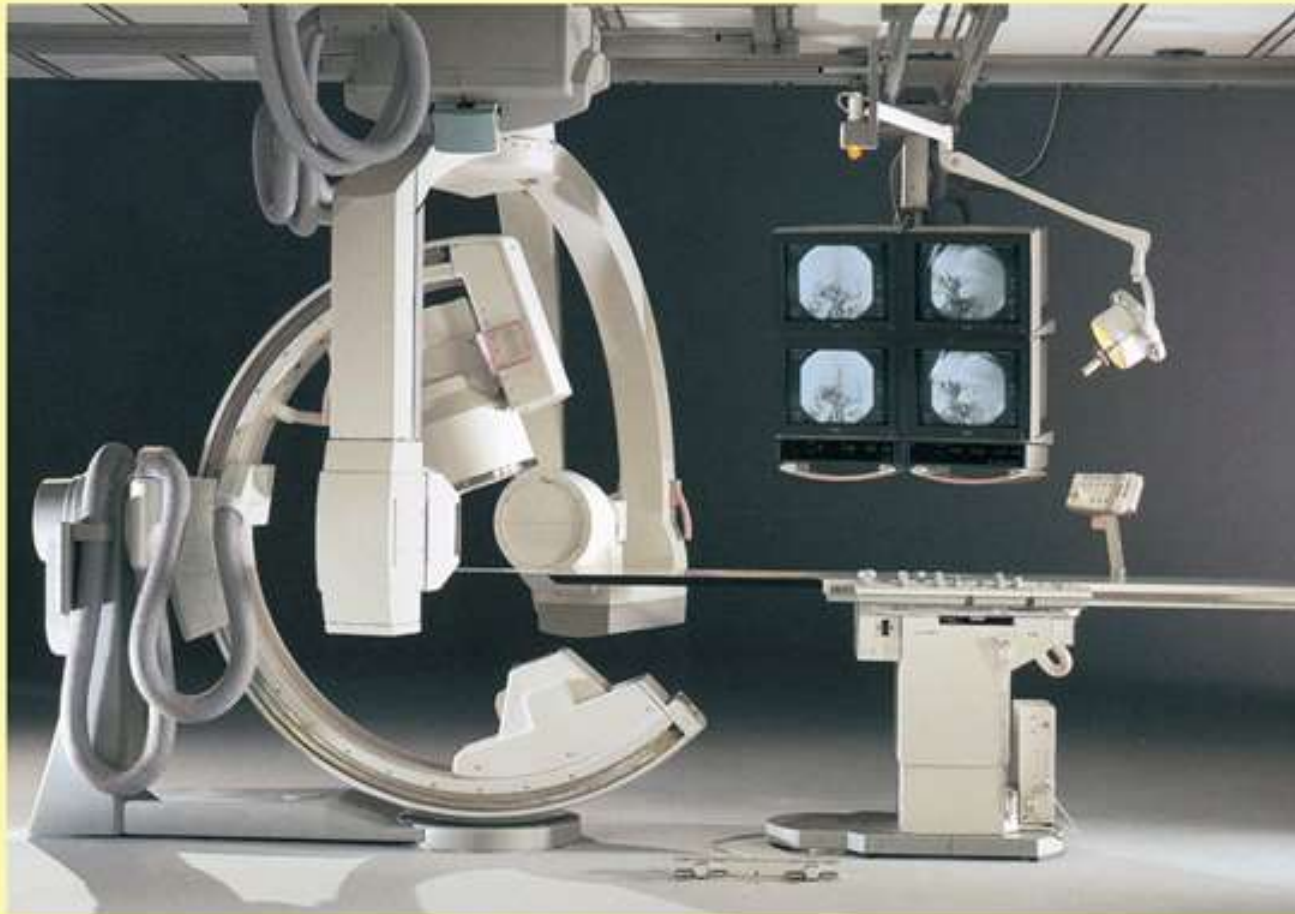
Copyright © 2003, Mosby, Inc. All Rights Reserved.

What is this?

- Maintain flow rates
 - Includes heating device
- (Discuss purpose of heating device)



Angiographic Imaging Equipment

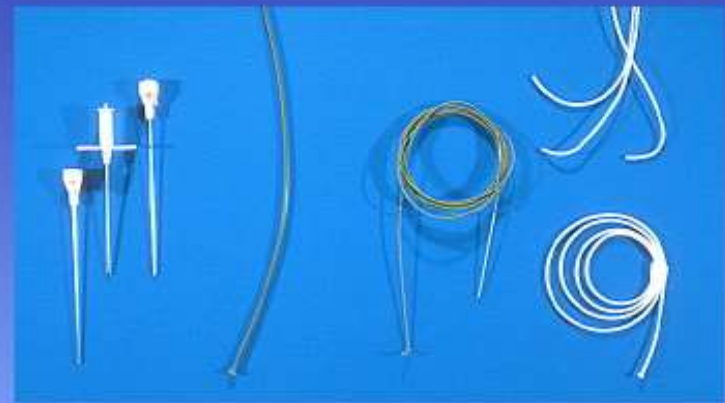
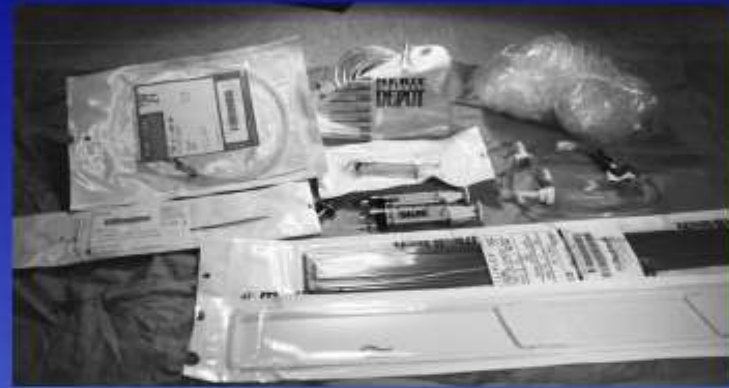
General angiographic room with biplane C-arm digital imaging

Other Supplies for Angiography


Additional Equipment and supplies

- Syringes
- Connective tubing
- Disposable fluids reservoir
- Catheters
- Guide wires
- Dilators
- Arterial needles




Needles

- Vascular access needles
- Size based on external diameter of needle
- Allows for appropriate Guidewires matching
 - So internal diameter must also be known



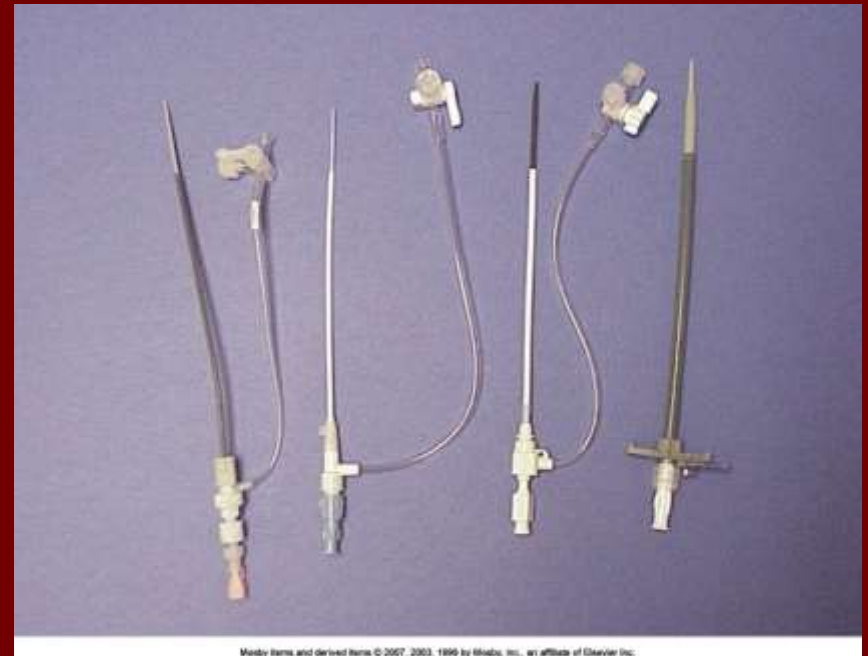Guidewires

- Used as a platform over which a catheter is to be advanced
- Once positioned guidewire is fixed and catheter is advanced until it meets the tip of the guidewire
- Mostly constructed on stainless steel & coated with Teflon



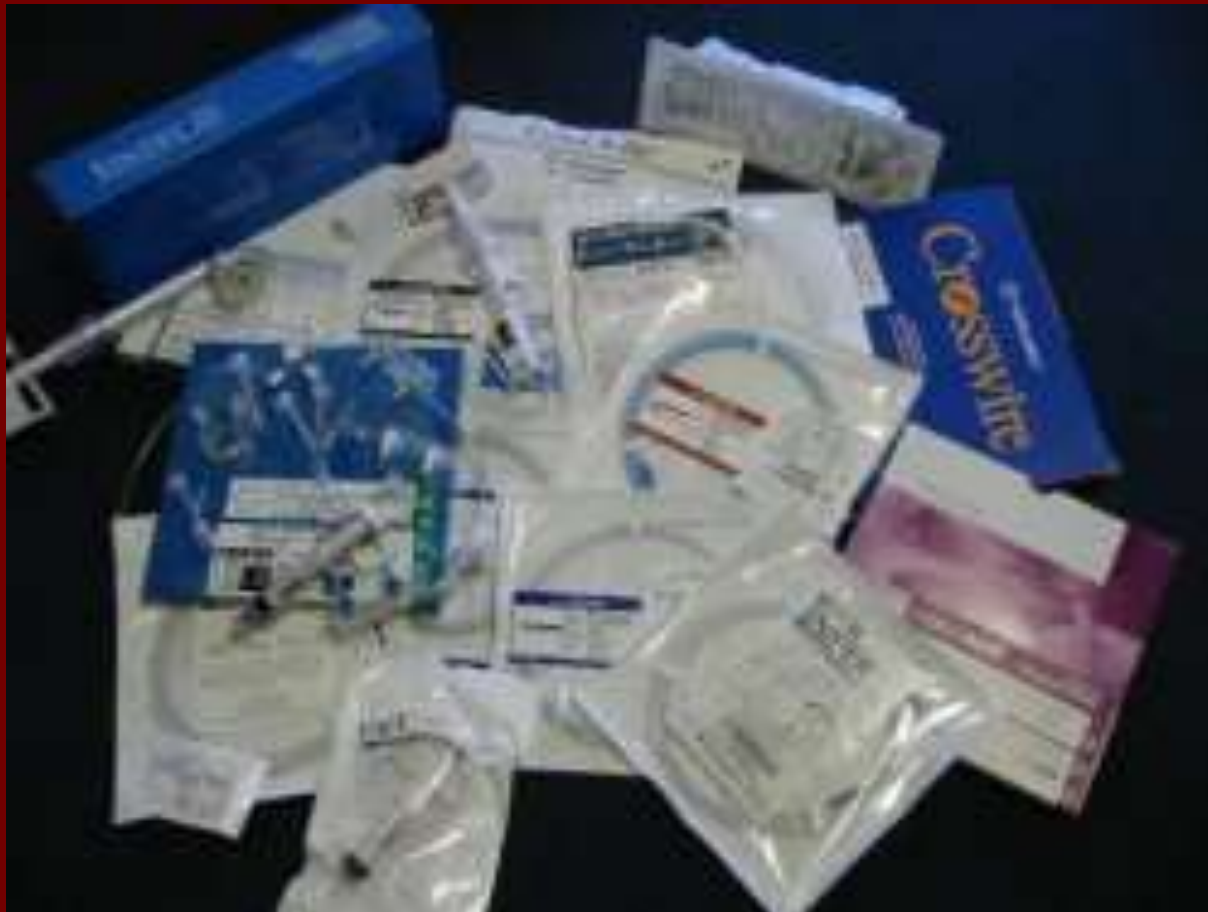Introducer Sheaths

- Short catheters used when multiple catheters will be used
- Placed in lieu of a catheter



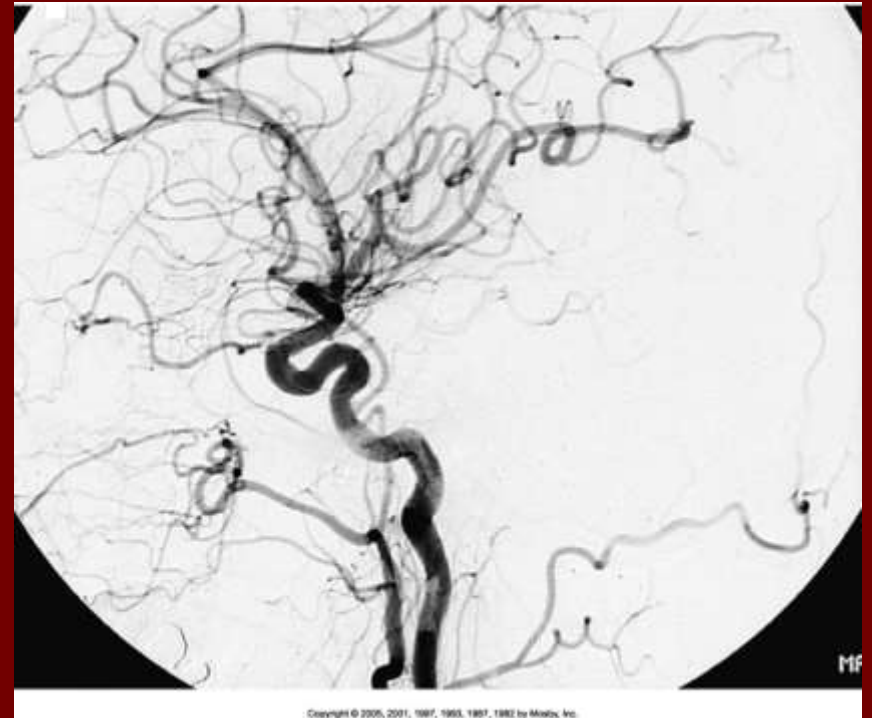
Meady items and derived items © 2007, 2003, 1996 by Meddy, Inc., an affiliate of Elsevier Inc.

Catheters

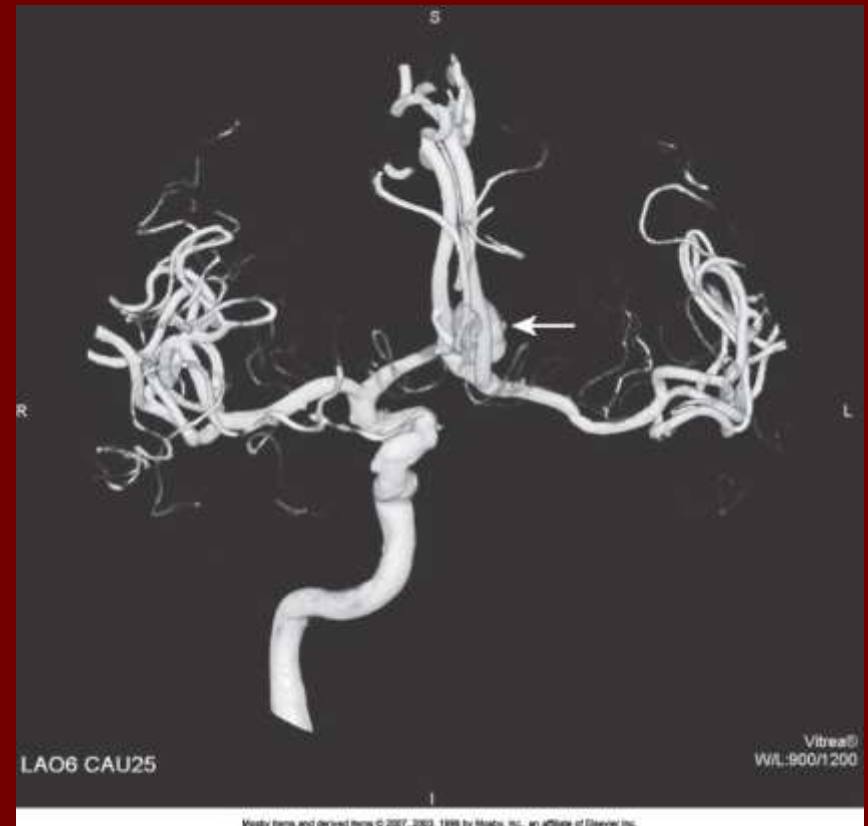
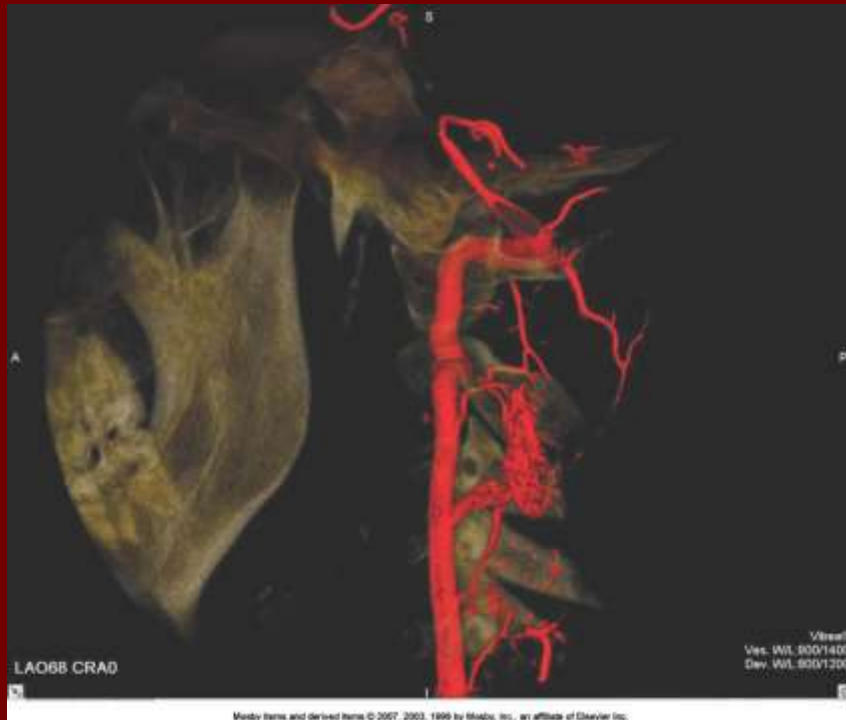

DSA

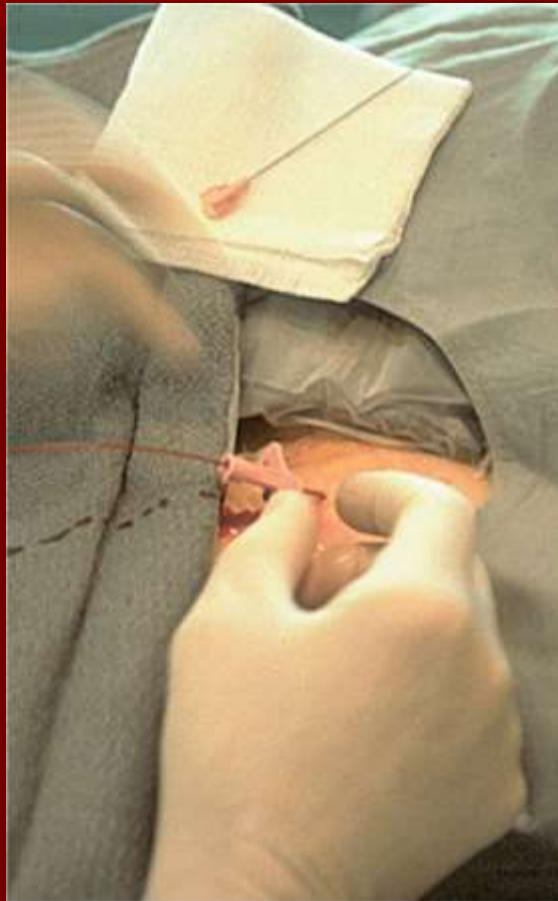- A subtraction mask is taken before contrast injected
- Each of digitized image is from the mask
- Images acquired form
 - 1 image every 2-3 sec
 - Up to 30 images per sec



Three Dimensional (3-D) Intraarterial Angiography



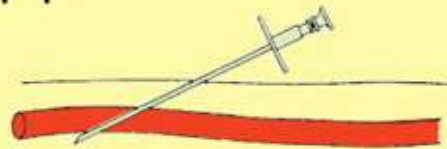
What Method is this?



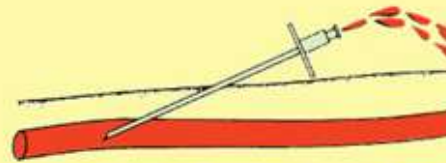
Copyright © 2005, 2001, 1997, 1993, 1987, 1982 by Medtronic, Inc.

Catherization: Selinger Technique

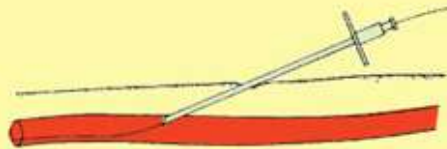
- Method of vessel catheterization
- Six step process



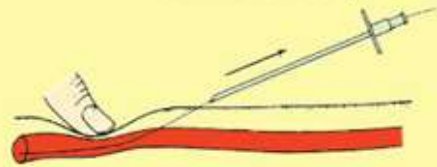
Step 1. Insertion of needle (with inner cannula)



Step 2. Placement of needle in lumen of vessel (inner cannula removed)



Step 3. Insertion of guide wire



Step 4. Removal of needle



Step 5. Threading of catheter to area of interest



Step 6. Removal of guide wire



Pre-Procedure

- PT's are usually limited to a liquid diet and routine medications
- Adequate hydration
- An IV line placed
 - Sedative may be given
- History taken and vitals taken
- Informed consent

Preparing the Patient Room

- Must be extensively cleaned
- Equipment checked
- Room thoroughly stocked
- Extra supplies as needed

Radiation Protection

- PT is protected by no less than 2.5 mm of Aluminum
- Beam restriction
- Avoidance of repeat exposure
- Cardinal rules
 - Time
 - Distance
 - Shielding

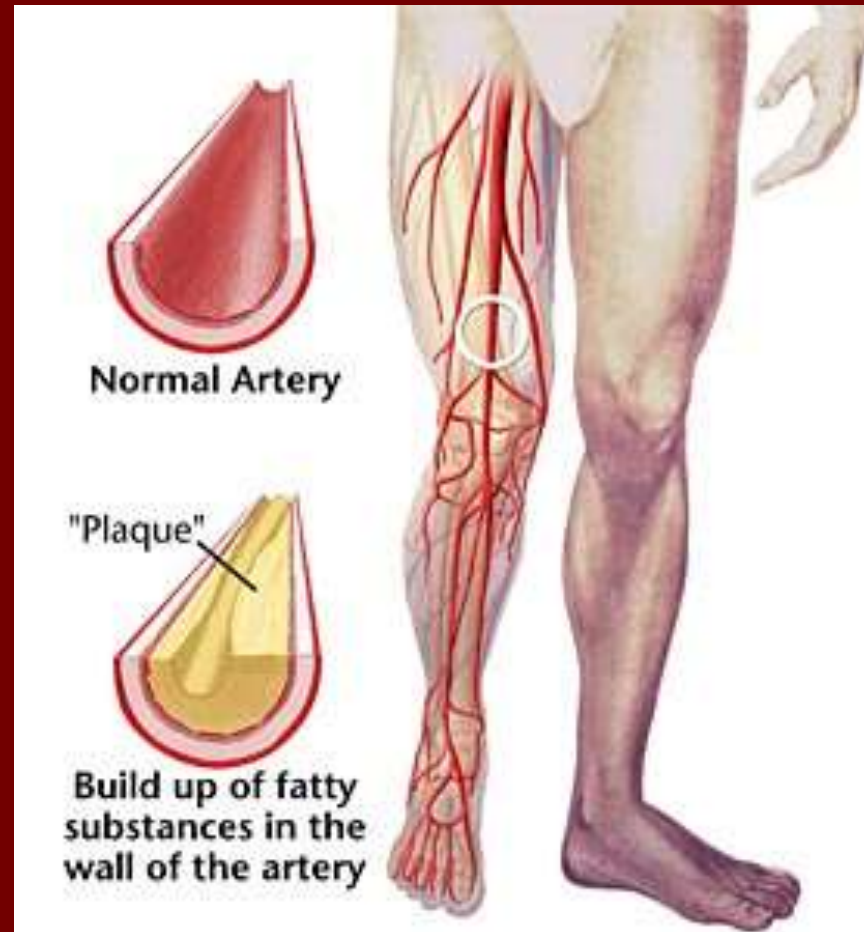
Post Procedure

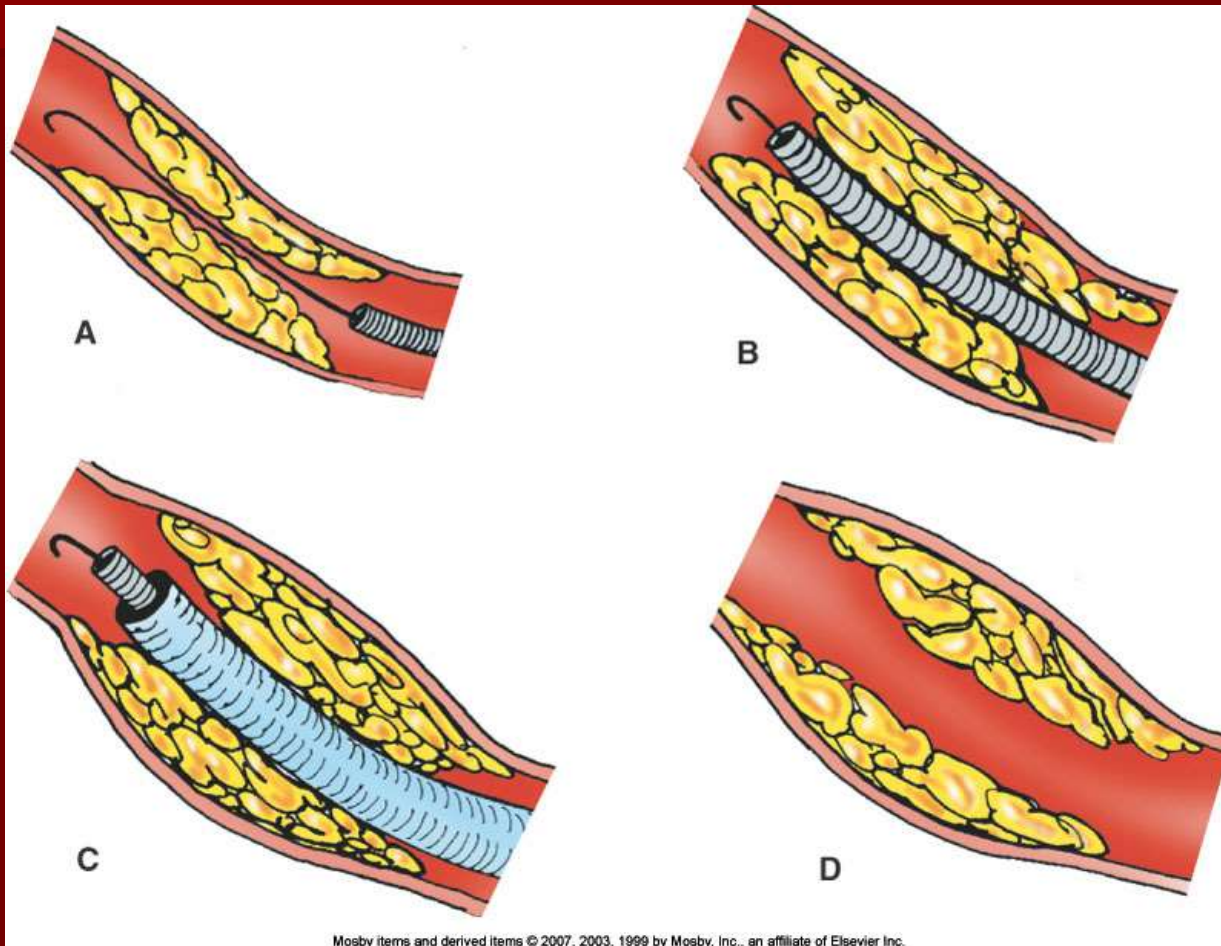
- PTs usually can resume normal activity after 24 hours
- Most often can go home after 24 hours
 - Because internal bleeding can be life threatening
- Vitals are monitored
- Puncture site is monitored for bleeding

Stent Placement

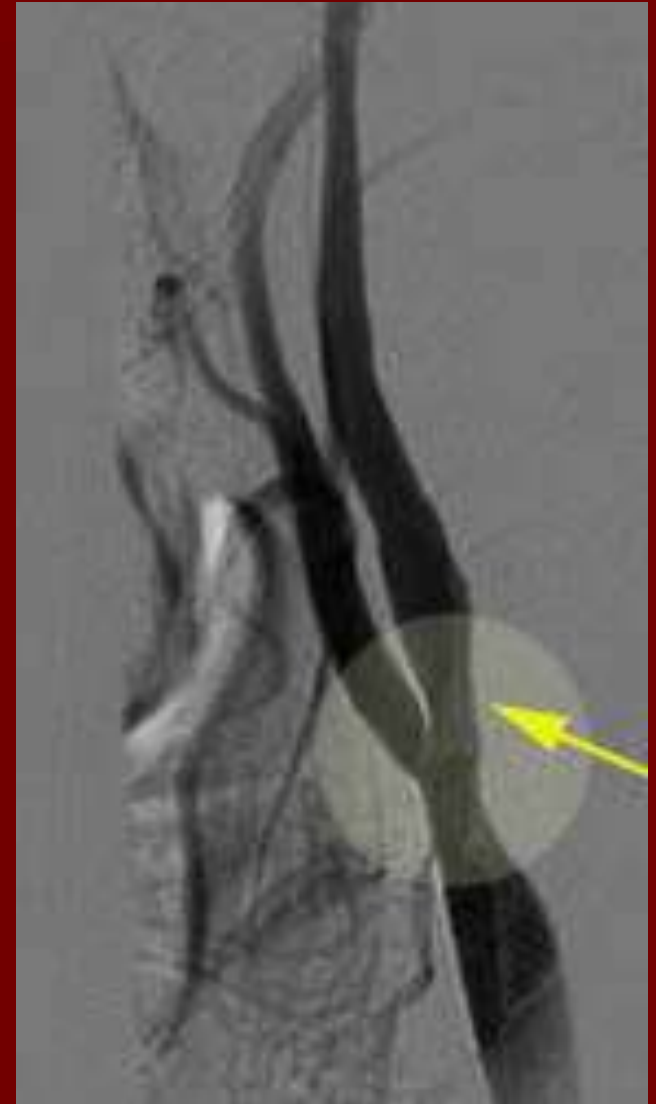
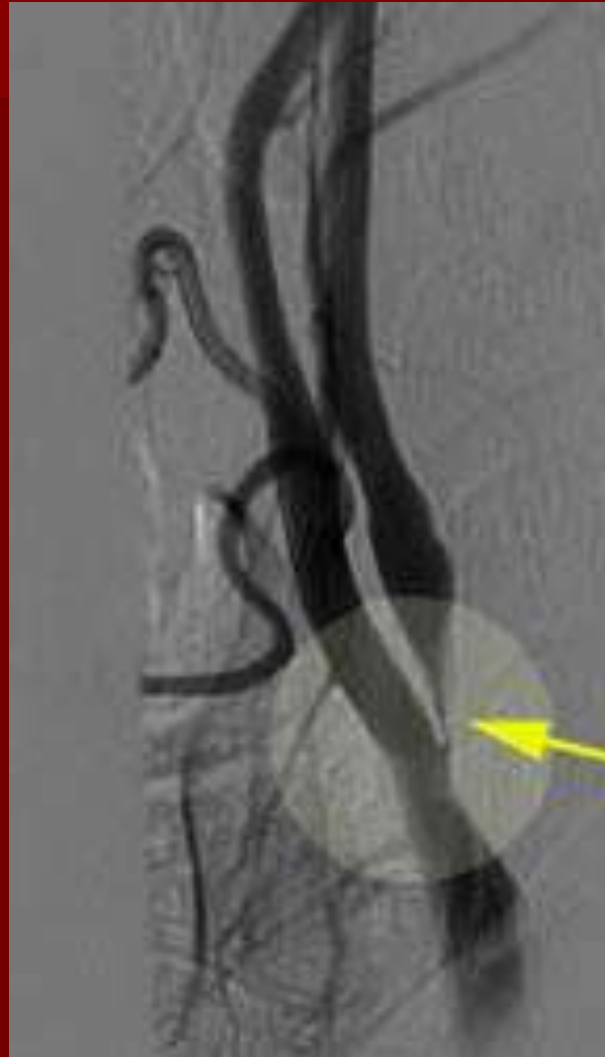- http://images.google.com/imgres?imgurl=http://www.nhlbi.nih.gov/health/dci/images/stent_restenosis.gif&imgrefurl=http://www.nhlbi.nih.gov/health/dci/Diseases/stents/stents_all.html&usg=__xDIbsaX9JhuYbpVojLcz19apr-I=&h=513&w=450&sz=59&hl=en&start=20&tbnid=vWwqaG-RNW7M-M:&tbnh=131&tbnw=115&prev=/images%3Fq%3Dabdominal%2Bstents%26gbv%3D2%26hl%3Den

Leg Atherosclerosis

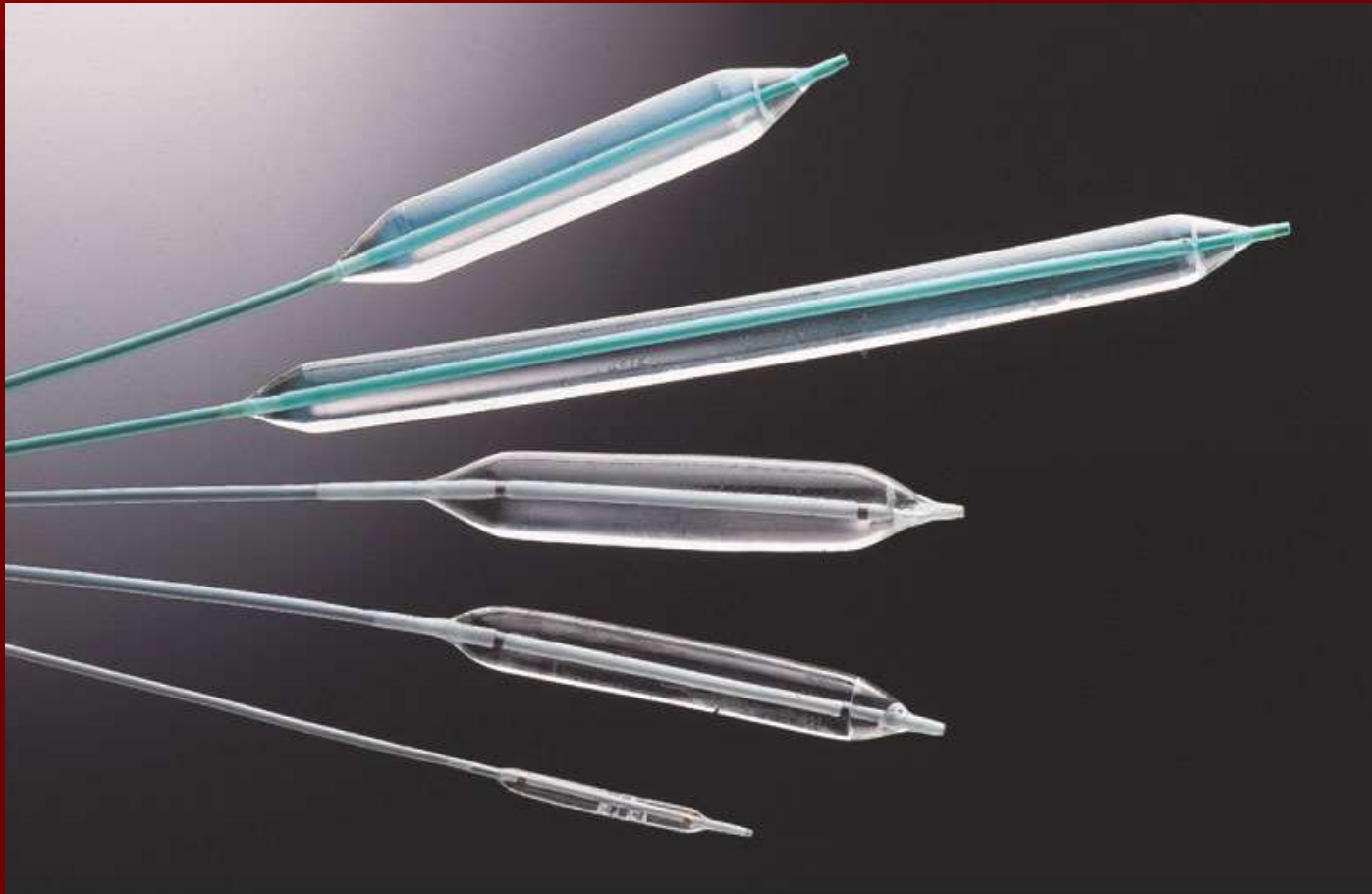




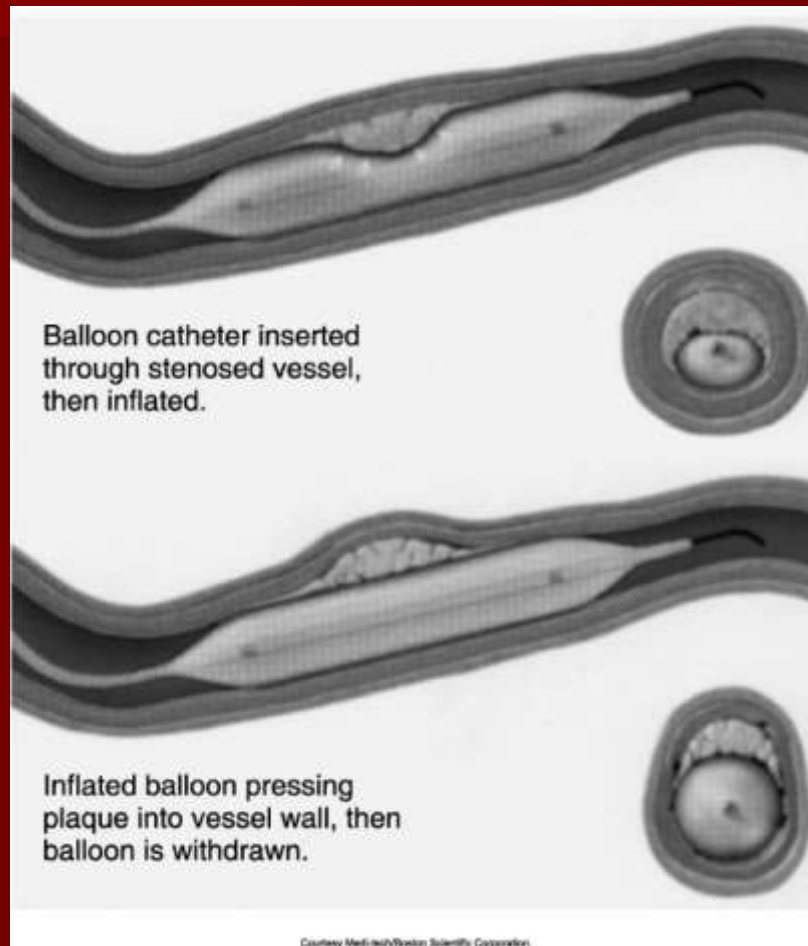
Carotid Atherosclerosis



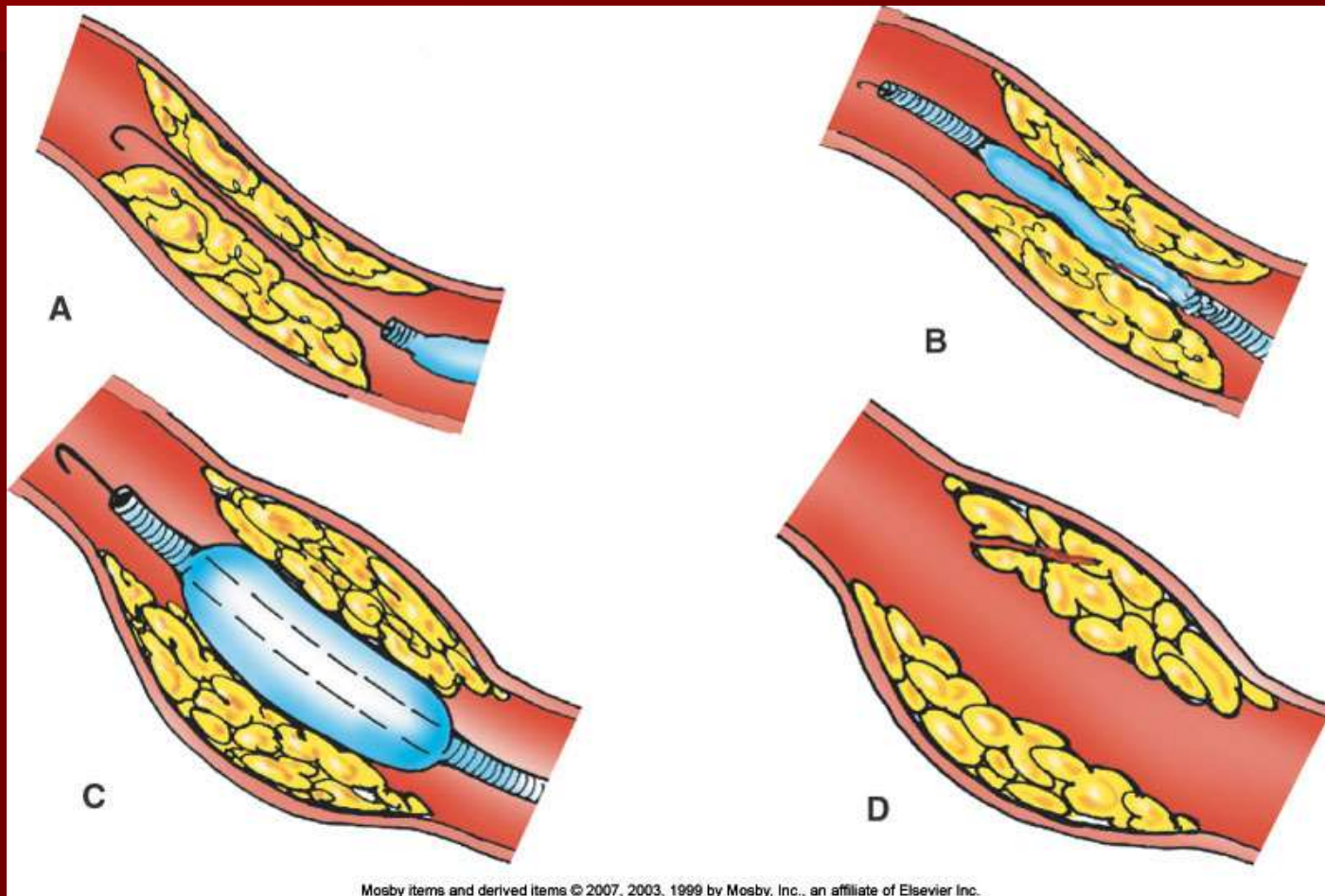
Balloon Angioplasty



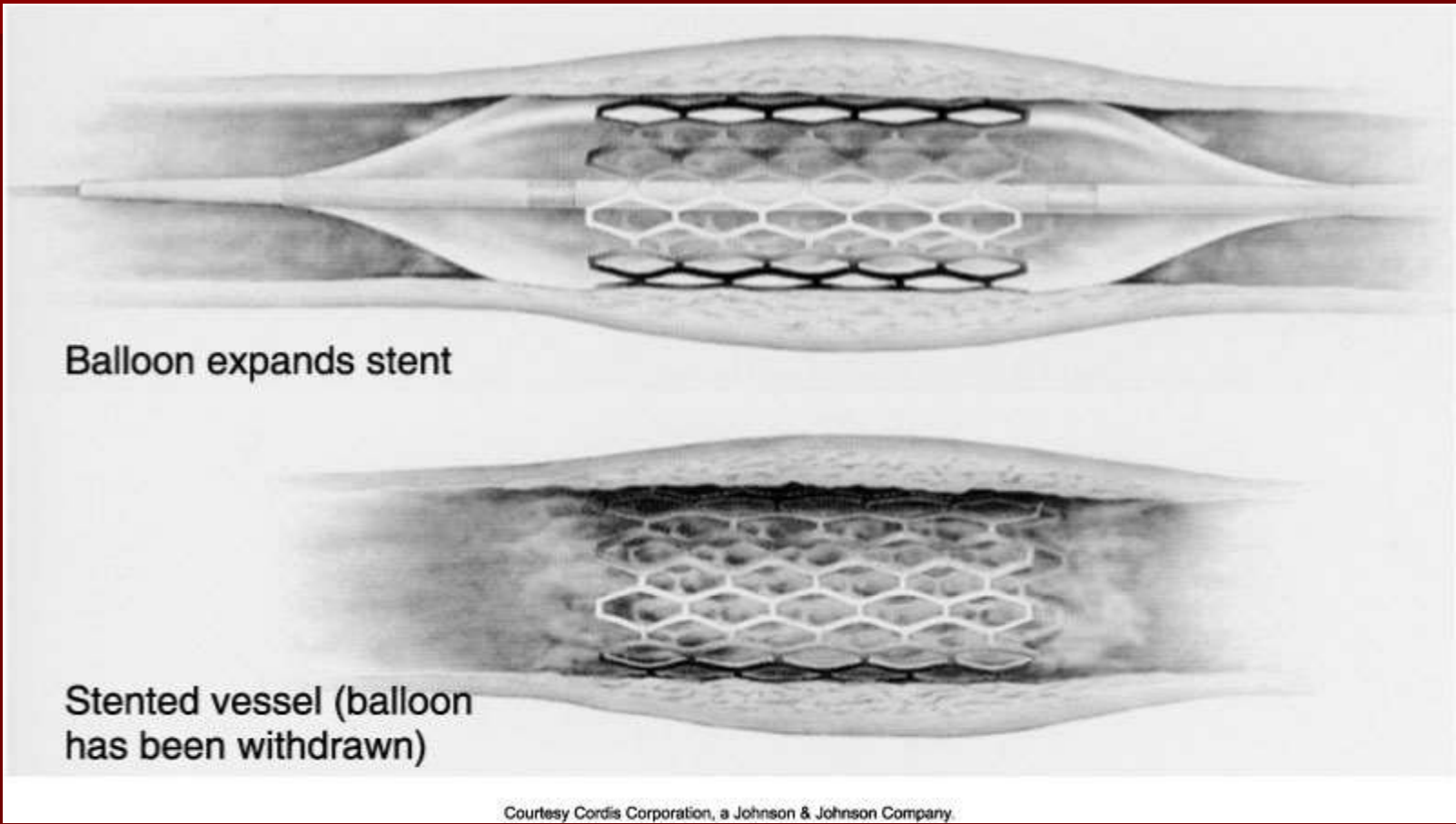
(Courtesy Bard Radiology.)



Balloon Angioplasty Procedure



Placing a Stent after Angioplasty with Balloon



Intravascular Stents

